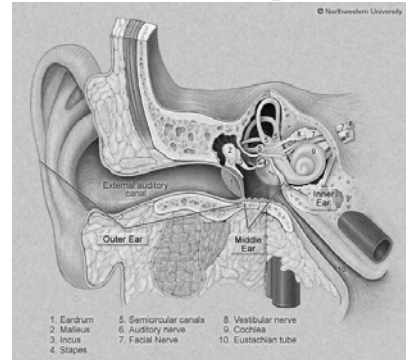


Otologic Dizziness (Dizziness from Ear)

Timothy C. Hain, MD

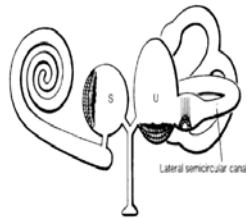
Northwestern University, Chicago
t-hain@northwestern.edu

Structures of importance



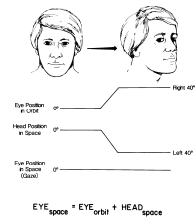
The ear is an inertial navigation device

- Semicircular Canals are rate sensors.
- Otoliths (utricle and saccule) are linear accelerometers
- Bilateral symmetry means redundant design.



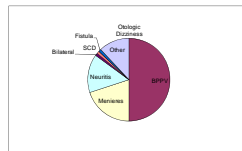
Vestibular Reflexes

- VOR: Vestibulo-ocular reflex
- VSR: Vestibulospinal reflex



Otologic (Ear) Dizziness

- BPPV (benign paroxysmal positional vertigo) -- about 50% of otologic, 20% all
- Meniere's disease -- about 20%
- Vestibular neuritis and related conditions (15%)
- Bilateral vestibular loss (about 1%)
- SCD and Fistula (rare: but worth knowing)



Positional Vertigo The most common syndrome

■ Benign Paroxysmal Positional Vertigo (BPPV)

- Orthostatic hypotension
- Central positional nystagmus
- Low CSF pressure syndrome

Benign Paroxysmal Positional Vertigo (BPPV)

61 Y/O man slipped on wet floor.

LOC for 20 minutes.

In ER, unable to sit up because of dizziness

Hallpike Maneuver: Positive

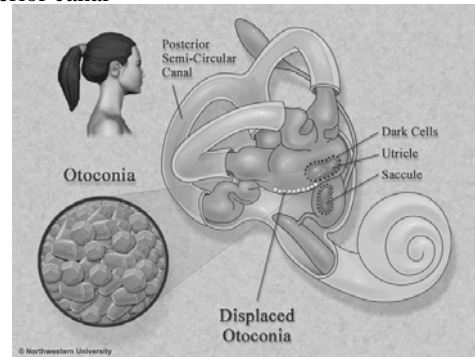
Positional Vertigo Dix-Hallpike Maneuver



Benign Paroxysmal Positional Vertigo (BPPV)

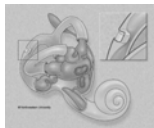
- 20% of all vertigo
- Brief and strong
- Provoked by change of head position
- Definitively diagnosed by Hallpike test

BPPV Mechanism: Utricular debris migrates to posterior canal



BPPV treatment

- Medication (e.g. antivert) – minor benefit
 - May avoid vomiting by pretreating
- Excellent response to PT
- Surgery – canal plugging if rehab fails (need more rehab after plug)



Unilateral Vestibular

- Vestibular Neuritis/Labyrinthitis (common)
- Meniere's disease (unusual, 1/2000 prevalence)
- Acoustic Neuroma (very rare)
- Vestibular paroxysmia

Vestibular Neuritis: Case

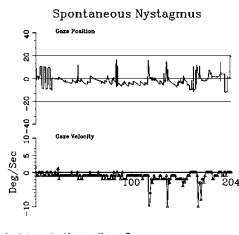
56 y/o woman began to become dizzy after lunch. Dizziness increased over hours, and consisted of a spinning “merri-go-round” sensation, combined with unsteadiness.

Vomiting ensued 2 hours later, and she was brought by family members to the ER.

Vestibular Spontaneous Nystagmus seen with video Frenzel Goggles



Vestibular Spontaneous Nystagmus recorded on ENG (Electronystagmography)



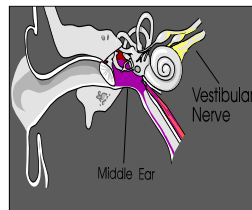
Aside : how to examine for SN

- Frenzel Goggles (best)
- Ophthalmoscope (good –but backwards)
- Gaze-evoked nystagmus (pretty good)
- Sheet of white paper (neat)



Vestibular Neuritis -- rx

- Disturbance of unknown cause (Viral? Vascular) involving vestibular nerve or ganglion.
- Disability typically lasts 2 weeks.
- Symptomatic Rx (meclizine, phenergan, benzodiazepine)
- Rehab if still symptomatic after 2 months.
- These patients can still get BPPV!



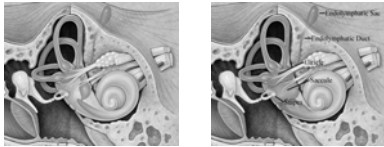
Meniere’s Disease

- Prosper Meniere
 - Fluctuating hearing
 - Episodic Vertigo
 - Fluctuating (roaring) Tinnitus
 - Aural Fullness
- About 1/2000 people in population
- Chronic condition – lasts lifetime



Etiology of Meniere's (Dogma)

- Dilation and episodic rupture of inner ear membranes (Endolymphatic Hydrops)
- As endolymph volume and pressure increases, the utricular/saccular and Reissner's membranes rupture, releasing potassium-rich endolymph into the perilymph causing cochlear/vestibular paralysis



Meniere's disease – symptoms

- Progressive hearing loss -- sometimes go deaf
- Episodic vertigo – out for several days
- Ataxia – gradually increases
- Visual sensitivity →

Visual Sensitivity is common

- Sensory integration disorder – upweight vision, downweight everything else
- Grocery store, Omnimax, Target, etc
- Typical of disorders with intermittent vestibular problems



Otolithic Crises of Tumarkin

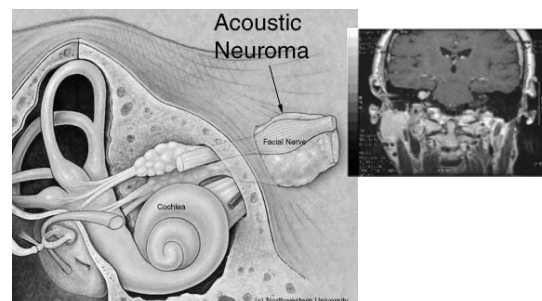
- Drop attacks
- Go from upright to on floor in fraction of second
- No LOC
- Very dangerous
- Destructive treatment



Treatments of Menieres

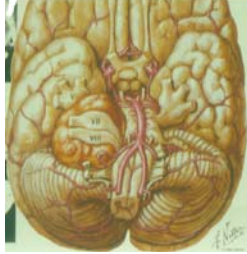
- Medical management –
 - Usually ineffective
- Bad rehab candidate while fluctuating
- Surgery
 - Low dose gentamicin treatment works nicely
 - High dose gentamicin treatment (overkill)
- Rehab useful post destructive treatment

Acoustic Neuroma



Acoustic Neuroma

- Cause of unilateral vestibular loss
- Rare cause of unilateral loss
- Generally also deaf on one side
- Slowly progressive – little or no vertigo



Treatment of Acoustic Neuroma

- Watchful waiting (about 25%)
- Operative removal (about 50%) – losing ground
- Gamma Knife (about 25%) – gaining ground because effective and noninvasive
- Good rehab candidate

Vestibular Paroxysmia (AKA microvascular compression)

- Irritation of vestibular nerve
- Quick spins
- Motion sensitivity
- May follow 8th nerve surgery
- Wastebasket syndrome in some cases ?

Clinical Diagnosis of MVC

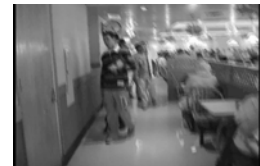- Quick spins
- May have nystagmus on hyperventilation
- Response to anticonvulsant
- No rehab potential

Bilateral Vestibular Loss

A stewardess developed a toe-nail infection. She underwent course of gentamicin and vancomycin. 12 days after starting therapy she developed imbalance. 21 days after starting, she was “staggering like a drunk person”. Meclizine was prescribed. Gentamicin was stopped on day 29. One year later, the patient had persistent imbalance, visual symptoms, and had not returned to work. Hearing is normal. She unsuccessfully sued her doctor for malpractice.

SYMPTOMS OF BILATERAL VESTIBULAR LOSS

- OSCILLOPSIA



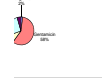SYMPTOMS OF BILATERAL VESTIBULAR LOSS

- ATAXIA



Bilateral Vestibular Loss Causes:

- Ototoxicity !
- Bilateral forms of unilateral disorders (e.g. bilateral vestib neuritis)
- Congenital (e.g. Mondini malformation)
- idiopathic



N=43, NMH 1990-1998

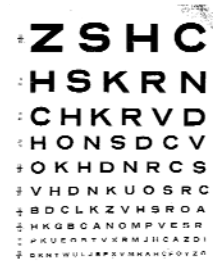DIAGNOSIS IS EASY

- History of recent IV antibiotic medication
- Eyes closed tandem Romberg is positive
- Dynamic illegible 'E' test (DIE) failed

---->

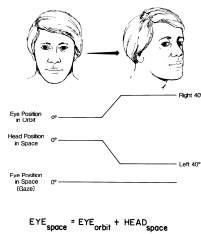
Dynamic Illegible 'E' test (DIE test)

- Distance vision with head still
- Distance vision with head moving
- Normal: 0-2 lines change.
- Abnormal: 4-7 lines change



Rapid Dolls failed

- VOR: Vestibulo-ocular reflex

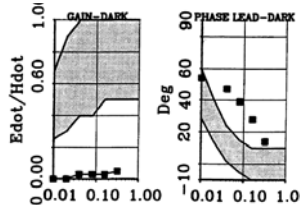
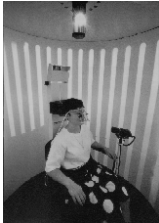

LABORATORY DIAGNOSIS

- ENG
- Rotatory chair


DIAGNOSIS Continued

- Rotatory chair confirms diagnosis but requires cooperation



DIAGNOSIS Continued

- ENG shows little or no response

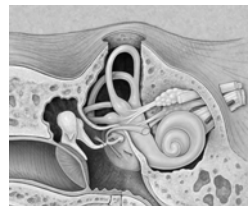


Treatment Bilateral

- No medical management (other than avoiding more damage)
- Outstanding rehab candidate
- Be prepared for a deposition

Perilymph Fistula and SCD (superior canal dehiscence)

Fluctuating conditions
No rehab until after surgery

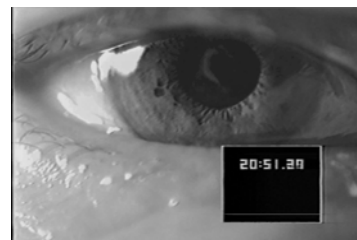

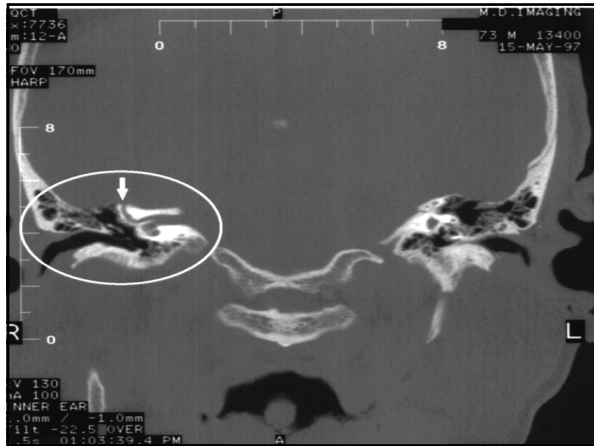- Superior Canal Dehiscence

Case: WS

Retired plastic surgeon, with impaired hearing related to war injuries, found that when he went to church, when organ was playing, certain notes made him stagger. His otolaryngologist noted that during audiometry (with hearing aid in), certain tones reliably induced dizziness and a mixed vertical/torsional nystagmus. This "Tullio's phenomenon" could be easily reproduced experimentally. MRI scan was normal.

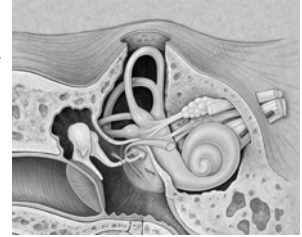
Tullio in SCD





Superior Canal Dehiscence

- Etiology:
 - Congenital bone defect (2% ?)
 - Trauma may exacerbate
- Treatment:
 - Surgical
 - » Plug
 - » Resurface

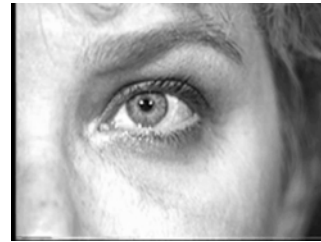


Diagnosis of SCD

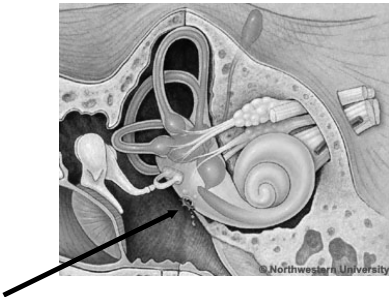
- History of sound and/or pressure sensitivity
- Tullio's and/or Valsalva (clinical)
- VEMP: Vestibular evoked myogenic potentials
- Temporal Bone CT scan (high resolution)

Case: KF

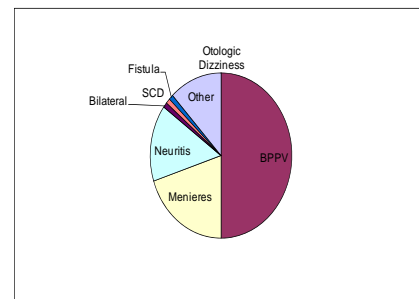
- After SCUBA diving, a young woman developed vertigo, aural fullness and tinnitus for 1 year.
- Symptoms were worsened by tragal pressure and straining. Surgery was performed.



A large round window fistula was found and symptoms completely resolved after a second surgery.



Summary of Otologic Vertigo



More details

Hain, T.C. Approach to the patient with Dizziness and Vertigo, Practical Neurology (Ed. Bilfer), 2002, 2008. Lippincott-Raven

More movies

www.dizziness-and-balance.com